

Emily Harmon MD<sup>1</sup>, Theresa Bowling, MD<sup>1</sup>, Vlad Frenk MD<sup>1</sup>, David Maduram MD PhD<sup>1</sup>

<sup>1</sup>Department of Anesthesiology, St. Vincent's Medical Center, Bridgeport CT, USA; St. Vincent's Medical Center, Bridgeport CT, USA

## Introduction

Breast reconstruction surgery by deep inferior epigastric perforator (DIEP) flap surgery results in significant pain following disruption of the anterior abdominal wall. Although this postoperative pain is traditionally treated with opioid medications, it is critical to identify and implement opioid-sparing clinical pathways given the incidence of opioid-related adverse events as well as the ongoing opioid epidemic. In this poster, we report the results of a retrospective case series of patients undergoing DIEP flap reconstruction in which a multimodal anesthetic regimen where ultrasound-guided quadratus lumborum (QL) blocks and pectoralis I and II (PEC I, II) blocks were used to provide robust opioid-sparing postoperative analgesia. Our main outcome measure was assessment of postoperative pain scores and opioid requirements at 24, 48 and 72 hours after the end of surgery. As secondary endpoints, we also looked at length of hospital stay. Written consent for publication of non-identifying medical information and Health Insurance Portability and Accountability Act authorization was obtained from all patients.

## Methods & Results

We reviewed medical records of three patients who underwent DIEP flap reconstruction surgery between Feb 16, 2021 to March 9, 2021 at St. Vincent's Medical Center [Bridgeport, Connecticut]. The demographic data of all patients in this sample were recorded. In the postoperative period, VAS scores on movement were measured at 24, 48, and 72 hours postoperatively. Postoperative morphine equivalent requirements were noted and recorded. All patients in this series received general anesthesia with a preoperative QL block and an intraoperative PEC I/II block. As part of a multimodal regimen, all patients received preoperative oral gabapentin, acetaminophen, and celecoxib, as well as intravenous dexamethasone 10mg and ketamine 0.25 mg/kg at the beginning of the case and ketamine 0.25mg/kg q4 hours for the duration of the procedure. Anesthesia was maintained with intravenous propofol, with or without sevoflurane at the discretion of the provider.

## Methods & Results (continued)

Patients received intravenous sedation with 2-4mg of midazolam in the preoperative area, and bilateral QL blocks were placed with the patient in the prone position as described by in literature using a total of fifteen milliliters of 0.25% bupivacaine admixed with fifteen milliliters of 1.3% liposomal bupivacaine. After induction of general endotracheal anesthesia, either unilateral or bilateral PEC I, II blocks as indicated by the intended procedure were performed, as described in literature. Intravenous acetaminophen 1000mg and diazepam 5mg were given at the end of the procedure. After completion of the surgery, all patients were taken to the postanesthesia care unit (PACU) and then to an inpatient care unit. Post-operative pain was treated with scheduled oral acetaminophen, gabapentin, and celecoxib, oral diazepam and opioids as needed, and IV opioids for breakthrough pain.

Hospital record data from DIEP flap reconstruction patients were extracted and analyzed. Continuous data are expressed as medians (interquartile ranges), because of the non-normal distribution of this data set.

Three patients underwent DIEP flap reconstruction surgery with multimodal analgesic regimen inclusive of bilateral QL blocks. Patient data is shown in the table below:

Subject Number	Age (y)	Sex	Opioid Consumption in MME at 24h, 48h, 72h	Time to First Opioid (hours)	Pain Score at 24h
1	58	F	0,60,135	39.0	4
2	55	F	10,15,20	3.3	1
3	52	F	8,8,8	3.4	0

The median 24h pain score was 1. The median 24h postoperative opioid consumption was 8 mg of oral morphine milliequivalent units. None of the patients exhibited signs of local anesthetic systemic toxicity. Patient and surgeon satisfaction was high with the analgesia provided.

## Discussion

The QL block has been successfully used for abdominal and hip surgery; however, no published case series to date describes PEC / QL block use in DIEP flap reconstruction surgery. In this retrospective case series, a single-shot injection provided analgesia for the extensive abdominal wall reconstruction likely due to coverage of the T4 to T12/L1 dermatomes via the anterior and lateral cutaneous branches of the nerves that run in the fascial plane surrounding the quadratus lumborum and pectoralis muscles. These nerve blocks are safe, as the needle remains distant from major intrabdominal structures, such as the liver, kidney, and spleen, at all times. Other important elements of the anesthetic regimen included preemptive analgesic administration of neuropathic and spasmolytic agents, as well as low dose ketamine. Our findings on efficacy and safety of PEC / QL blocks for DIEP flap reconstruction are consistent with other studies of QL blocks for abdominal surgery. Although other fascial plane blocks have been shown to be effective for DIEP flap reconstruction, PEC / QL blocks may provide an unique advantage in terms of ease of performance and improved surgical coverage.

## Acknowledgements & References

Special thanks to Bill Lahiff for assistance with poster authorship and technical support.

- Børghlum, J., et al., Ultrasound-Guided Transmuscular Quadratus Lumborum Blockade. BJA: British Journal of Anaesthesia, 2013. 111(eLetters Supplement).
- Ueshima, H., H. Otake, and J.-A. Lin, Ultrasound-Guided Quadratus Lumborum Block: An Updated Review of Anatomy and Techniques. BioMed research international, 2017. 2017: p. 2752876-2752876.
- Blanco, R., M. Fajardo, and T. Parras Maldonado, Ultrasound description of Pecs II (modified Pecs I): A novel approach to breast surgery. Revista Española de Anestesiología y Reanimación, 2012. 59(9): p. 470-475.
- Abdou, S.A., et al., Are Transversus Abdominis Plane Blocks the New Standard of Care in Microsurgical Breast Reconstruction? A Systematic Review and Meta-analysis. Plastic and Reconstructive Surgery – Global Open, 2019. 7(8S-1): p. 25.
- Liu, X., et al., Quadratus lumborum block versus transversus abdominis plane block for postoperative analgesia in patients undergoing abdominal surgeries: a systematic review and meta-analysis of randomized controlled trials. BMC Anesthesiology, 2020. 20(1): p. 53.

Figure 1: Lorem ipsum dolor sit amet, consectetur adipiscing elit, sed do eiusmod tempor incididunt ut labore et dolore magna aliqua.

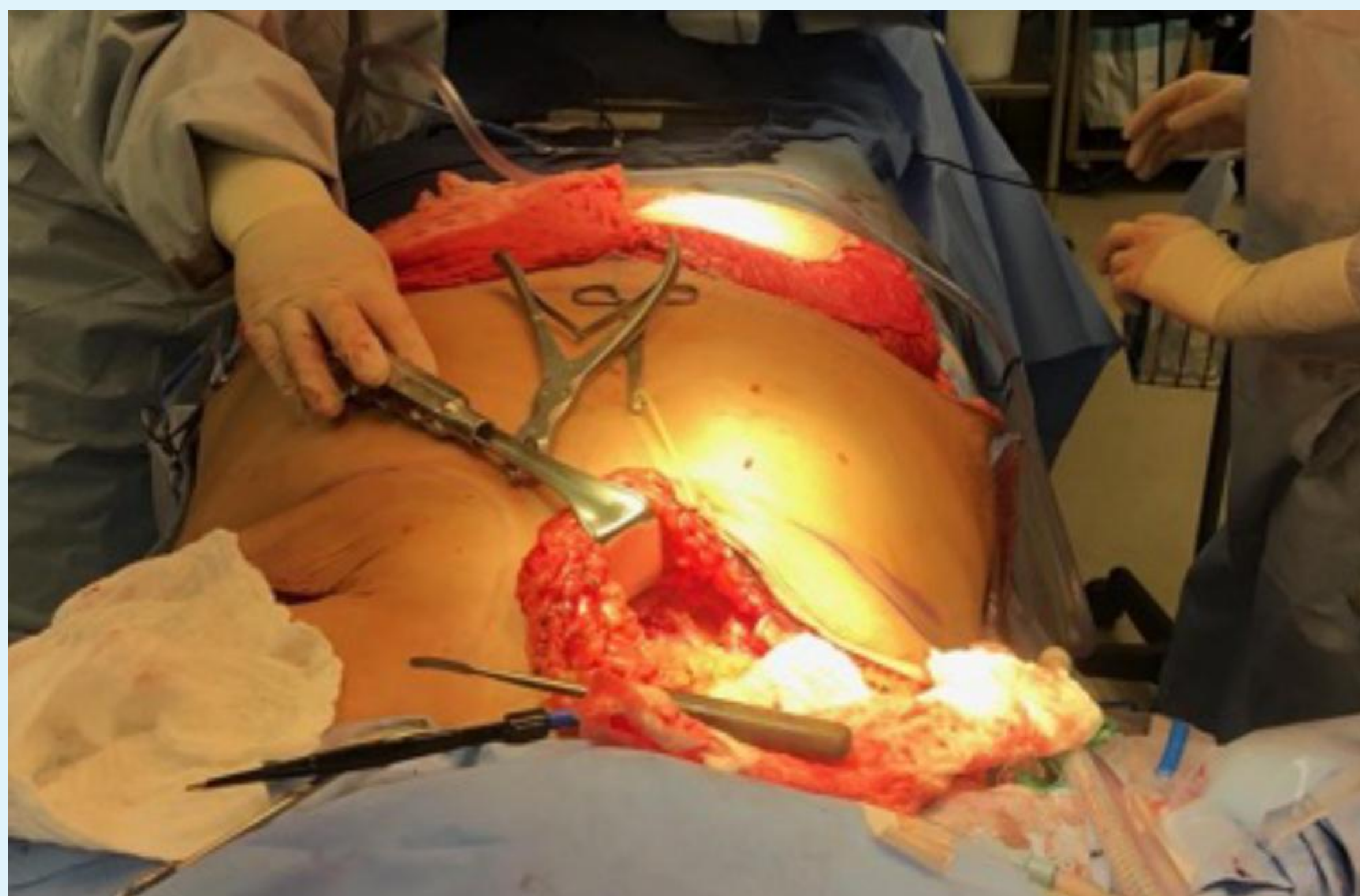
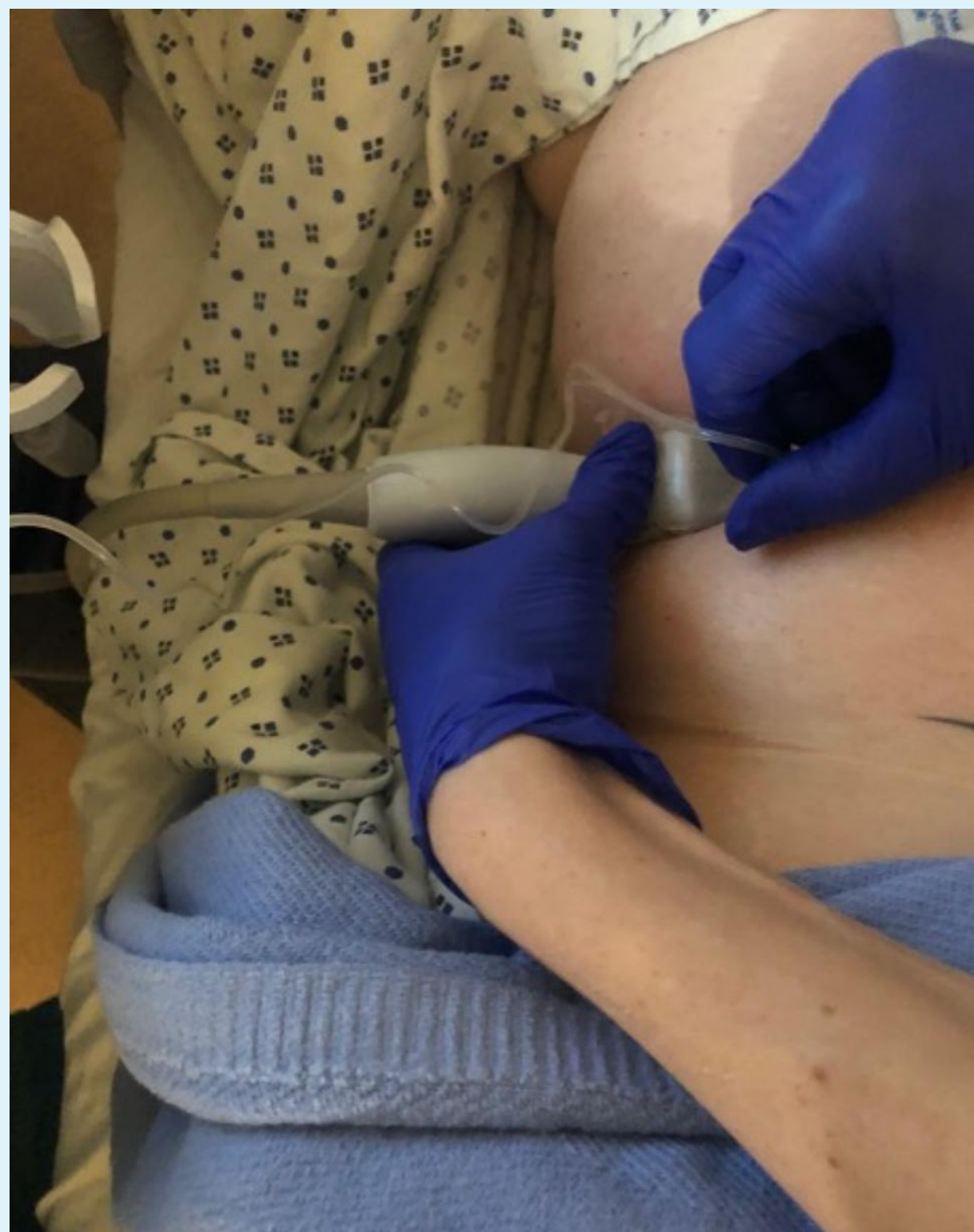

Figure 1: Lorem ipsum dolor sit amet, consectetur adipiscing elit, sed do eiusmod tempor incididunt ut labore et dolore magna aliqua.

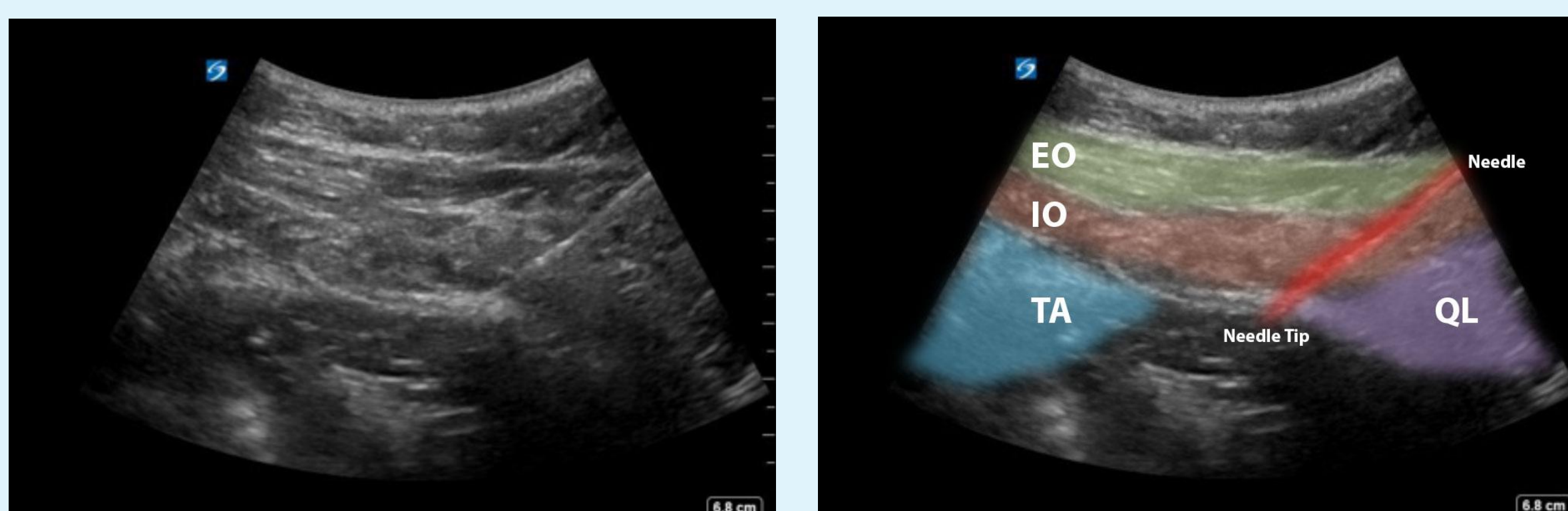


Fig 4a Ultrasound image illustrates anatomy during the QL block. Fig 4b Ultrasound image with false color overlay illustrates anatomy during the QL block. (Abbreviations: EO = External Oblique, IO = Internal Oblique, TA = Transversus Abdominus, QL = Quadratus Lumborum)